

JCM 6th July 2016

Case presentation

Princess Margaret Hospital

Dr Nyx WONG

Part I: Case presentation

M/63

- Found collapsed at PMH minibus stop at 10:00am, after attending FU at Orthopedics SOPD
- Vitals upon arrival at AED at 10:20 am
 - E1V1M1
 - BP 76/45mmHg, P 87 bpm, temp 35.9 °C
 - SpO2 was undetectable, RR 40
 - H'stix 7.1

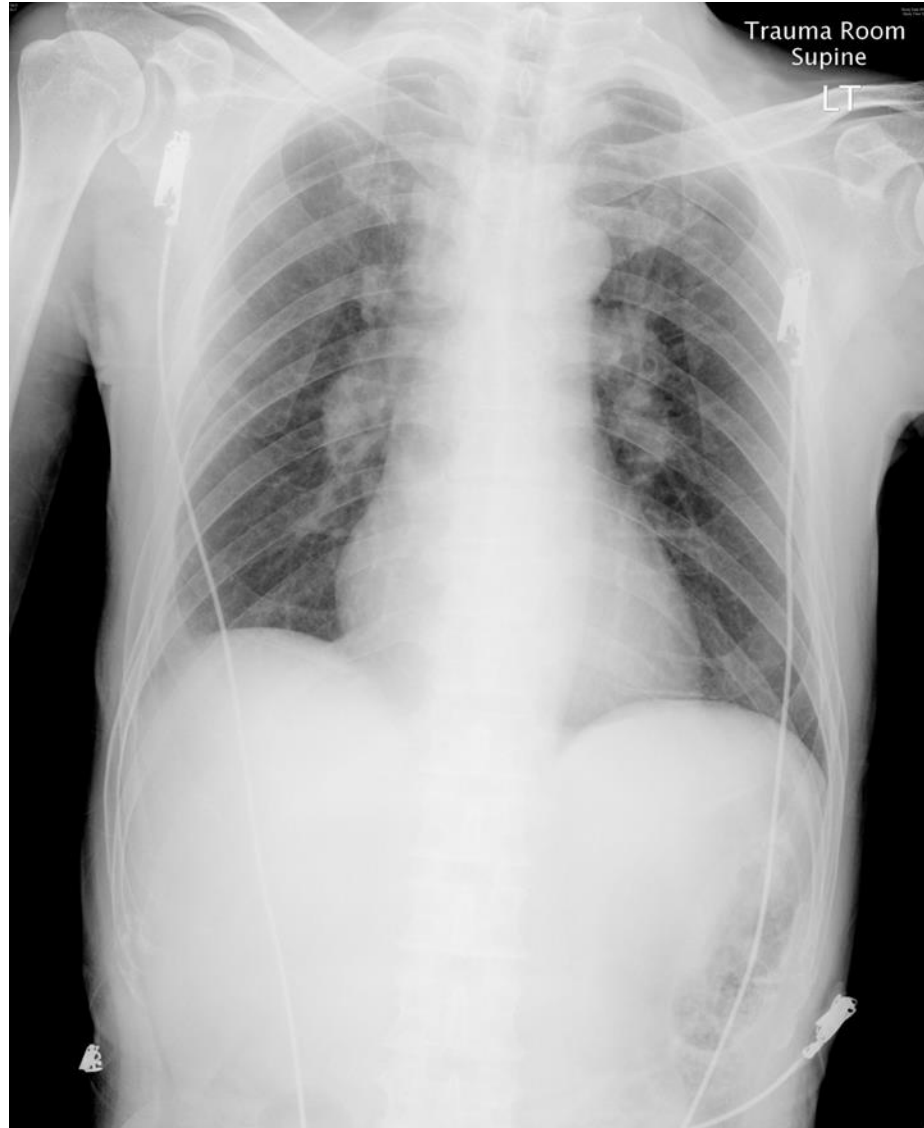Immediate management upon arrival to AED

- High-flow oxygen non rebreathing mask
- IVF NS Full Rate
- Cardiac Monitoring
- Blood Tests
- ECG

Few minutes after arrival to AED

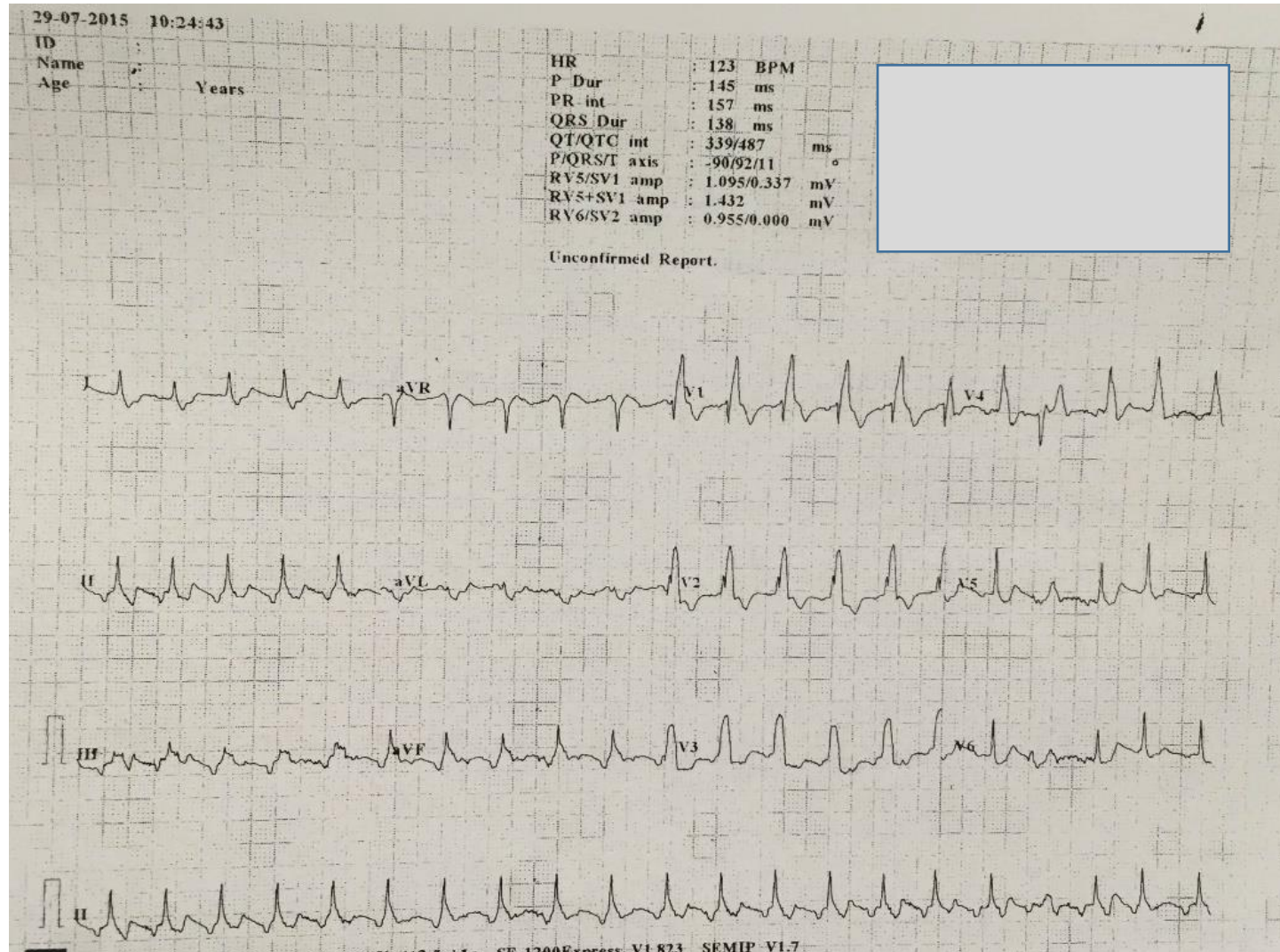
- Regained consciousness
- Complained of severe chest pain, no radiation, no back or abdominal pain
- BP 118/53, P 98, SpO2 87%
- Past medical history:
 - Rt patella fracture with ORIF done one month ago

CXR



- Clear lung field
- Mediastinum 7.2cm
- No pneumothorax

ECG after arrival at AED – Please Comment

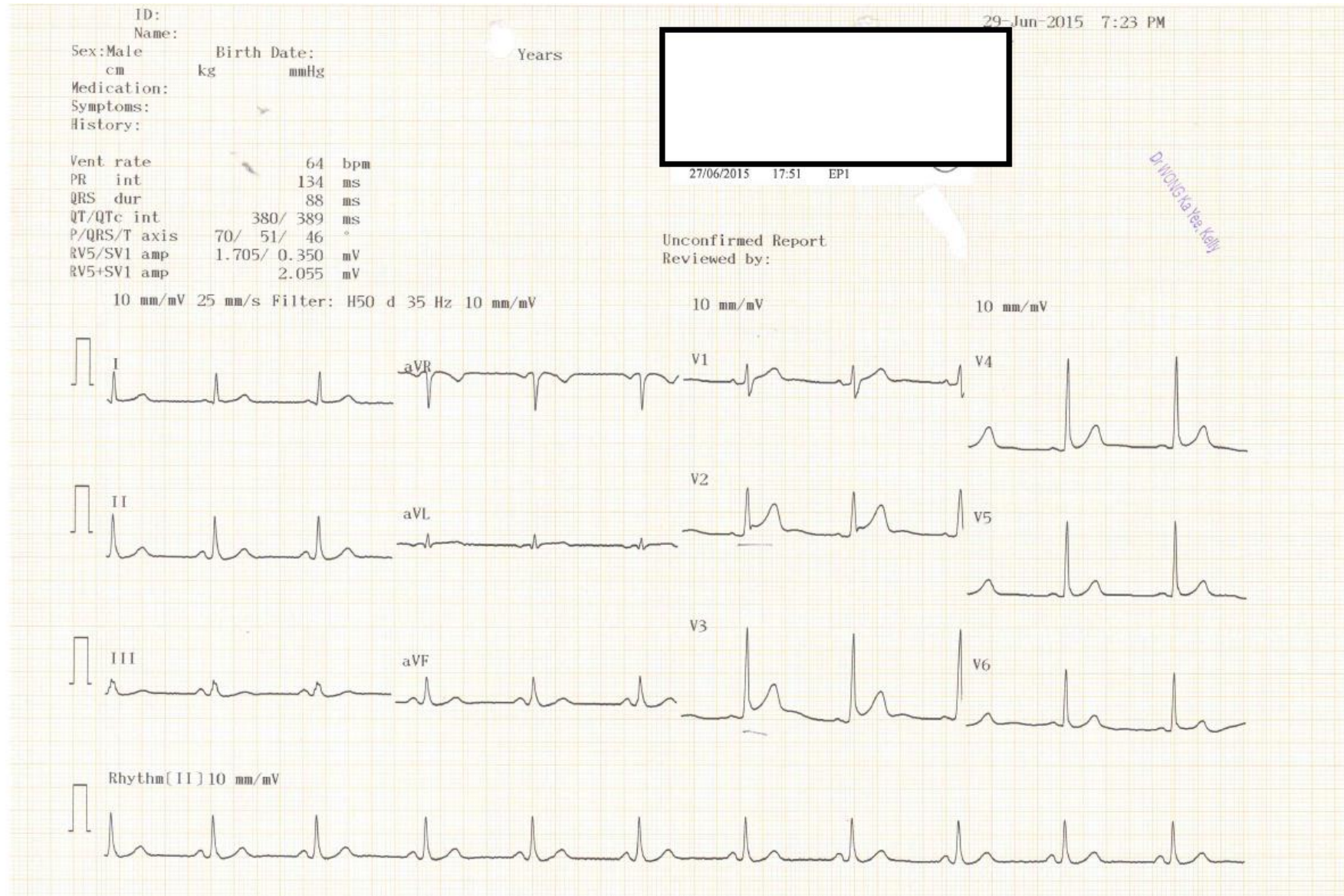


ECG Findings

- AF (? New)
- Tachycardia 123
- RBBB (? New)
- Axis: within normal range
- No classical S1Q3T3

Any DDx from the Audience ?

Old ECG



Progress

At 10:35 am: Morphine 2mg IV given for severe chest pain

At 10:45 am

- Unconscious again
- E1V1M1, BP 34/16, P 38, SpO2 70%
- Intubated under RSI (Rapifen 0.5mg, Etomidate 50mg, Suxamethonium 75mg)

Any comment from the audience regarding the choice of RSI ?

Progress

- Developed cardiac arrest 5mins after intubation
- Rhythm: PEA
- Adrenaline 1mg given, started chest compression by LUCAS

- ROSC at 10:56, down time 6 minutes
- BP 55/34, p 100, ETCO2 25
- Started Adrenaline infusion at 0.4 mg/hr

What is your working diagnosis now?

- Hx of operation one month ago
- Sudden collapse and chest pain
- Persistent desaturation
- Post-cardiac arrest with downtime 6 minutes
- Low BP on double inotropes (Dopamine and Adrenaline): 55/34 mmHg

ECG: new AF, Tachycardia, new RBBB

Bilateral jugular vein dilatation

What focused investigations would help you confirm this diagnosis?

What are the other life-threatening DDx ?

How would you exclude them ?

Bedside Echocardiogram & USG

- Dilated right ventricle
- No pericardial effusion
- No free intraperitoneal fluid
- No AAA
- Rt femoral vein was not fully compressible, no definite clots seen
- Echo performed by cardiologist:
 - Severely dilated RV with good function. Appearance is consistent with pulmonary embolism

How would you classify this PE ?

Classification of PE

- **Massive PE**

- sustained hypotension (**SBP<90 mmHg for at least 15 minutes** or requiring **inotropic support**, not due to a cause other than PE, such as arrhythmia, hypovolemia, sepsis, or left ventricular [LV] dysfunction), or
- **Pulselessness**, or
- persistent **profound bradycardia** (HR <40 bpm with signs or symptoms of shock)

- **Sub-massive PE**

- Acute PE without systemic hypotension (**SBP>90 mm Hg**) but with either RV dysfunction or myocardial necrosis.

Part II: Acute Management

Diagnosis? Massive Pulmonary embolism

BP 55/34, P 100, SpO2 100% despite increasing doses of inotropes and 2.5L of IVF

Cardiologist & ICU colleagues prefer to go for contrast CT thorax

Do you agree with them?

Discussion: how can we diagnose PE in R room?

- Pre-test Probability
 - History
 - Clinical Signs
 - Prediction rules
- Investigations
 - CXR
 - ECG
 - Echocardiogram
 - Blood Tests
 - Doppler USG for DVT

Pulmonary Embolism – clinical presentation

Symptoms

- Dyspnoea
- Hemoptysis
- Syncope
- Chest pain
- Cough

Signs

- Tachypnoea
- Hypoxia
- Tachycardia
- Cyanosis
- Elevated JVP

Prediction rules of PE

Table 2. The Revised Geneva Score*

Variable	Regression Coefficients	Points
Risk factors		
Age > 65 y	0.39	1
Previous DVT or PE	1.05	3
Surgery (under general anesthesia) or fracture (of the lower limbs) within 1 mo	0.78	2
Active malignant condition (solid or hematologic malignant condition, currently active or considered cured < 1 y)	0.45	2
Symptoms		
Unilateral lower-limb pain	0.97	3
Hemoptysis	0.74	2
Clinical signs		
Heart rate		
75–94 beats/min	1.20	3
≥95 beats/min	0.67	5
Pain on lower-limb deep venous palpation and unilateral edema	1.34	4
Clinical probability		
Low		0–3 total
Intermediate		4–10 total
High		≥11 total

* DVT = deep venous thrombosis; PE = pulmonary embolism.

Modified Wells criteria: clinical assessment for pulmonary embolism

Clinical symptoms of DVT (leg swelling, pain with palpation)	3.0
Other diagnosis less likely than pulmonary embolism	3.0
Heart rate >100	1.5
Immobilization (≥3 days) or surgery in the previous four weeks	1.5
Previous DVT/PE	1.5
Hemoptysis	1.0
Malignancy	1.0
Probability	
Score	
Traditional clinical probability assessment	
High	>6.0
Moderate	2.0 to 6.0
Low	<2.0
Simplified clinical probability assessment*	
PE likely	>4.0
PE unlikely	≤4.0

Data from van Belle, A, et al. JAMA 2006; 295:172.

Pulmonary Embolism Rule-out Criteria (PERC) rule

- age <50
- HR < 100 bpm
- SpO2 = 95% or above
- prior DVT or PE
- No recent surgery or trauma within last 4 weeks
- No hormone use
- No unilateral leg swelling
- No hemoptysis

false negative rate of 1.0%

sensitivity of 97.4%; specificity of 21.9%;

“Prospective multicenter evaluation of the pulmonary embolism rule-out criteria”. Journal of Thrombosis and Haemostasis 2008

Chest X-ray

- Only 12% of patients with PE have normal CXR at presentation
- Common findings:
 - pleural effusion
 - elevated diaphragm
 - Atelectasis
- Uncommon signs:
 - Fleisher sign
 - Hampton hump
 - Westermark's sign
 - Knuckle sign

An useful tool to
exclude other ddx

• Chest radiographic findings in patients with acute pulmonary embolism: observations from the PIOPED Study; 1993

ECG features

In patients with acute PE, ECG features with increased risk of circulatory shock and death

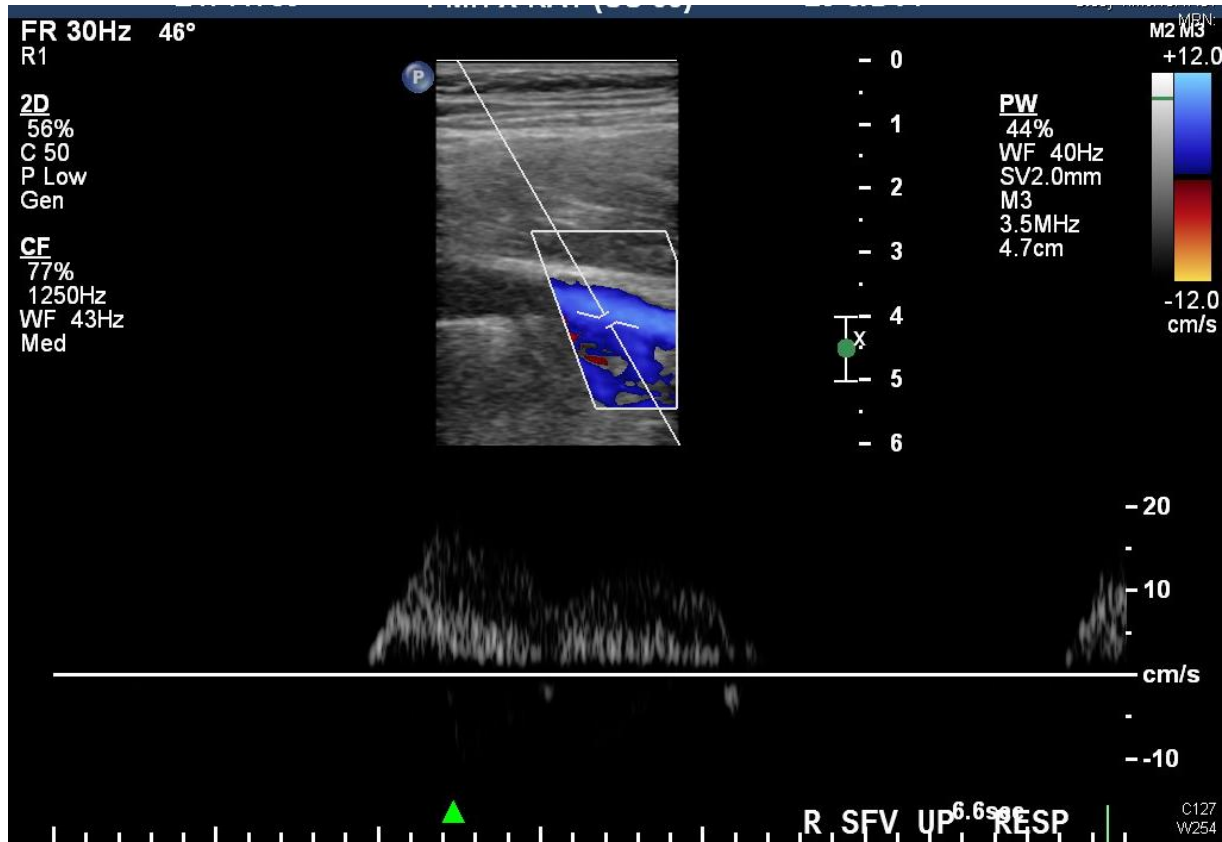
- Heart rate >100 bpm ← most common
- S1Q3T3
- New RBBB
- inverted T waves in V1–V4
- ST elevation in aVR
- atrial fibrillation/atrial flutter

non-specific and insensitive
in diagnosing PE

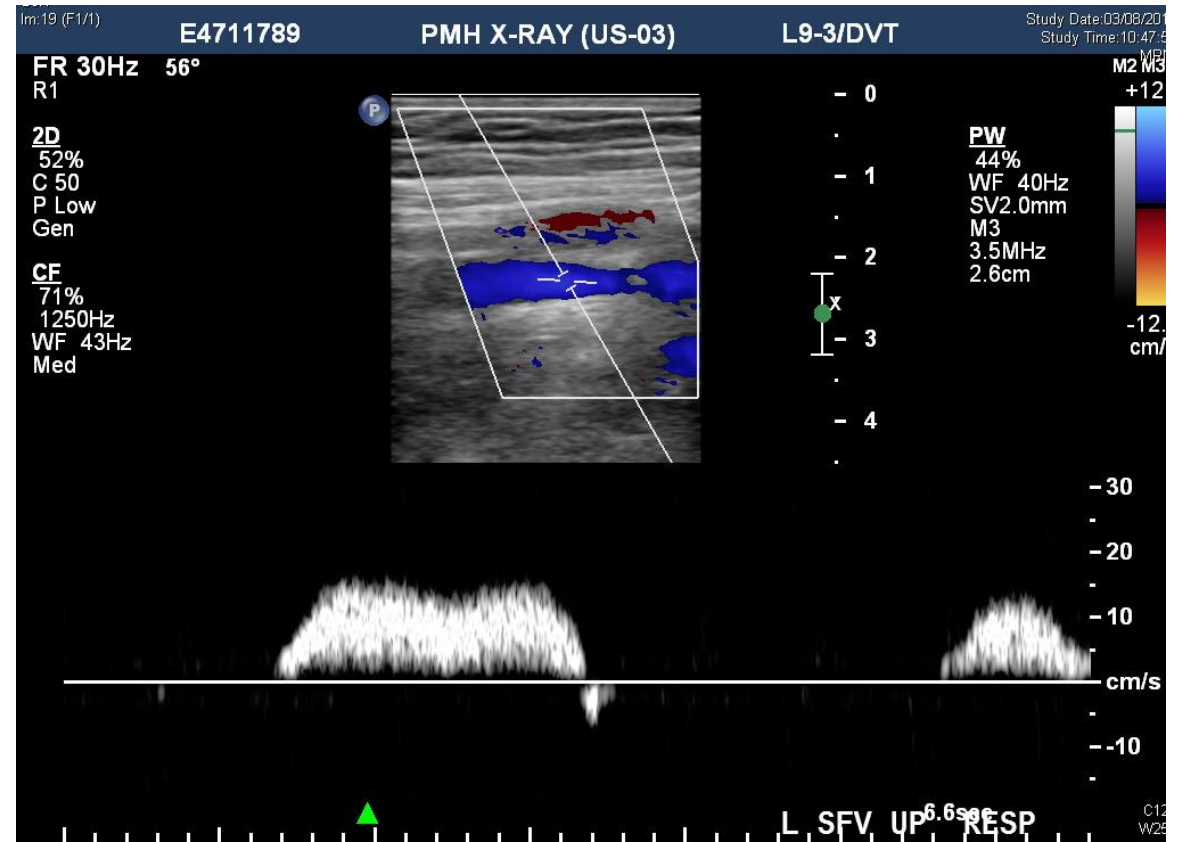
Findings From 12-lead Electrocardiography That Predict Circulatory Shock From Pulmonary Embolism: Systematic Review and Meta-analysis 2015

Academic Emergency Medicine **22** (10): 1127–1137

Respiratory Variation

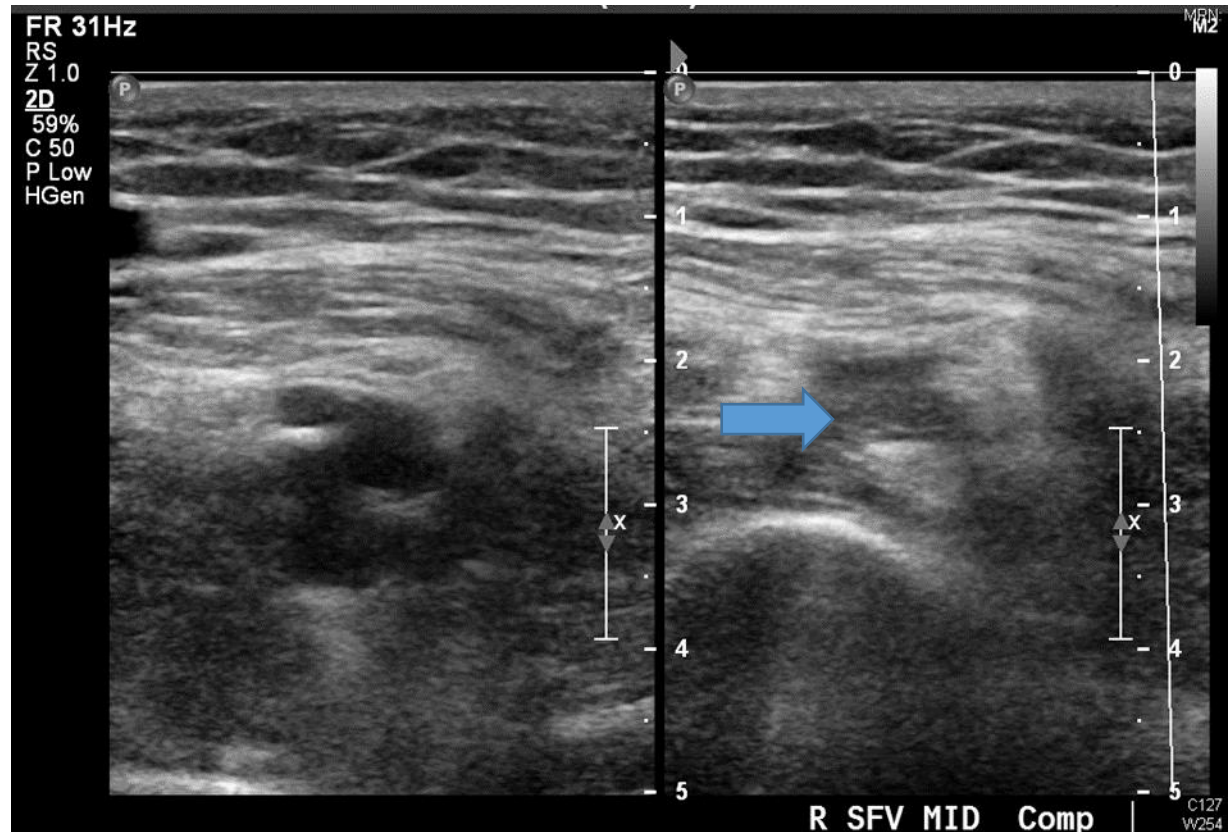
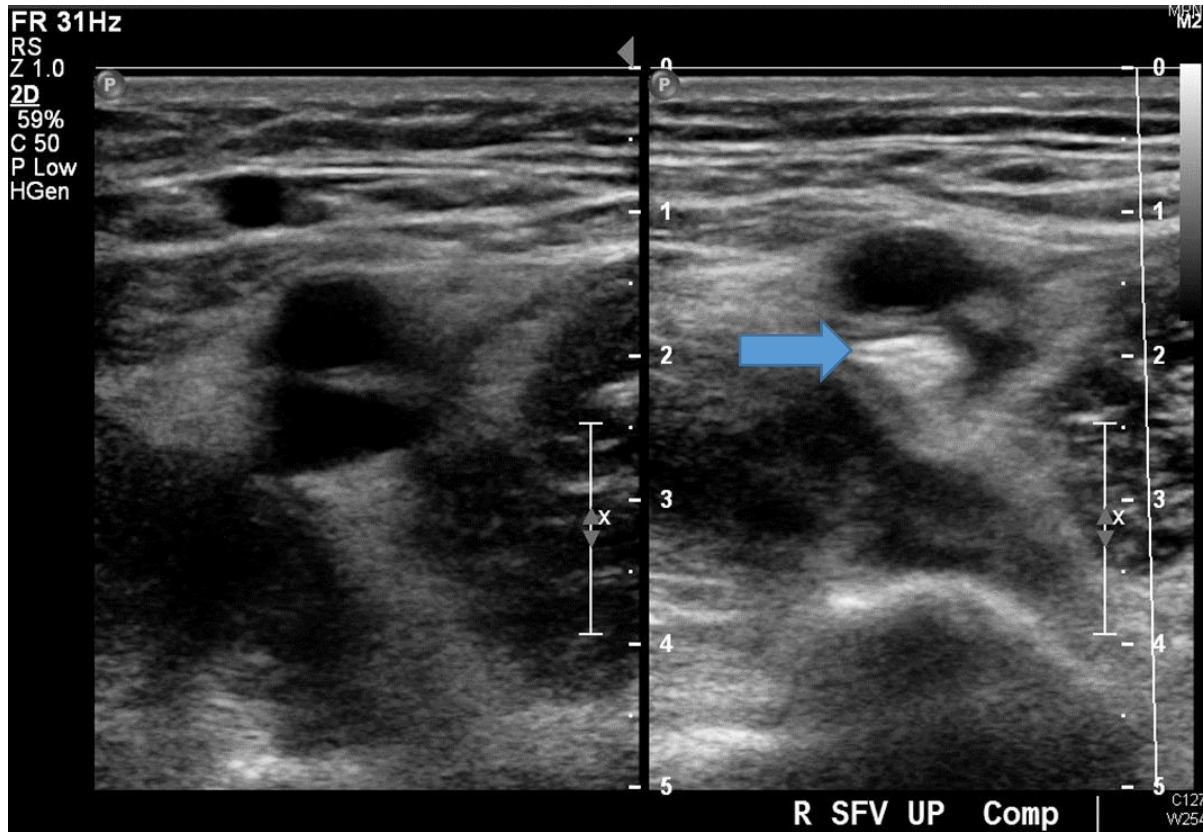


Right side

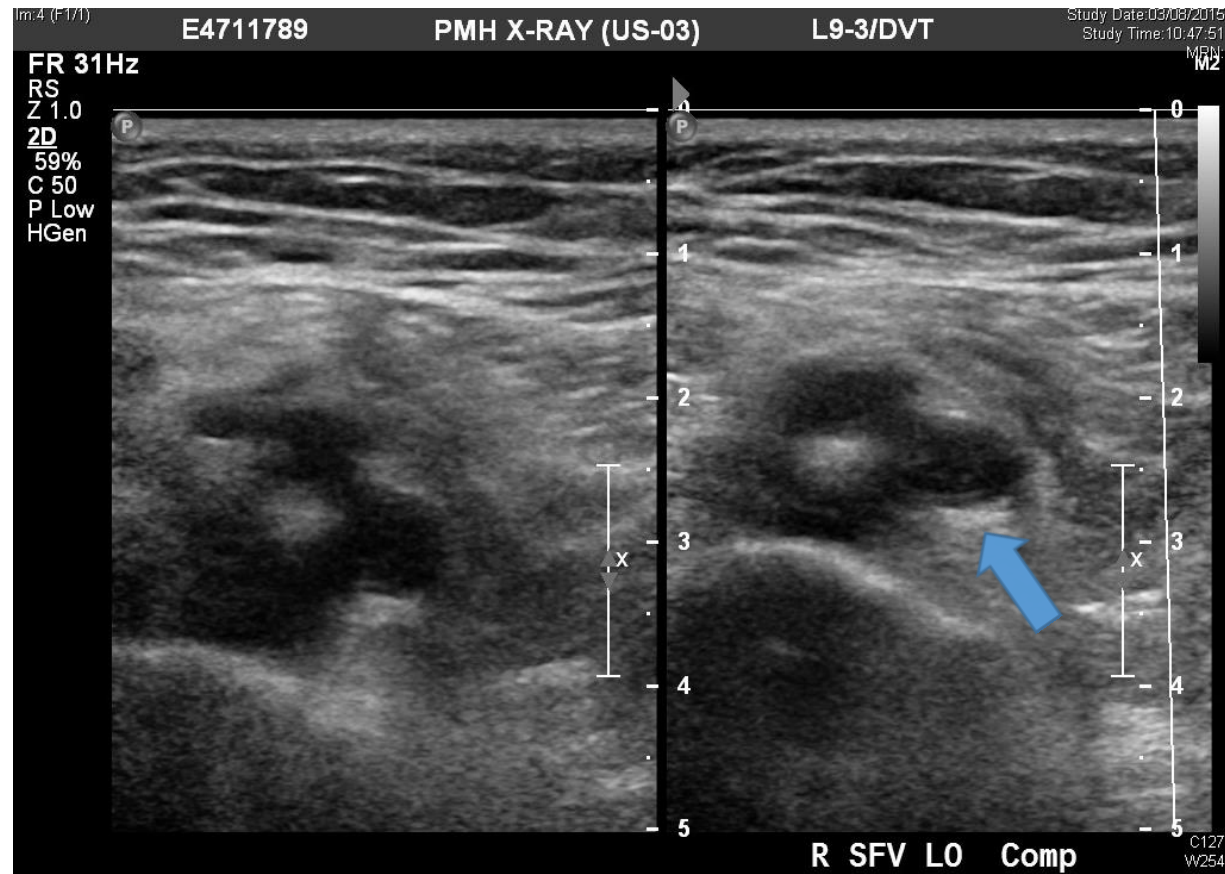


Left Side

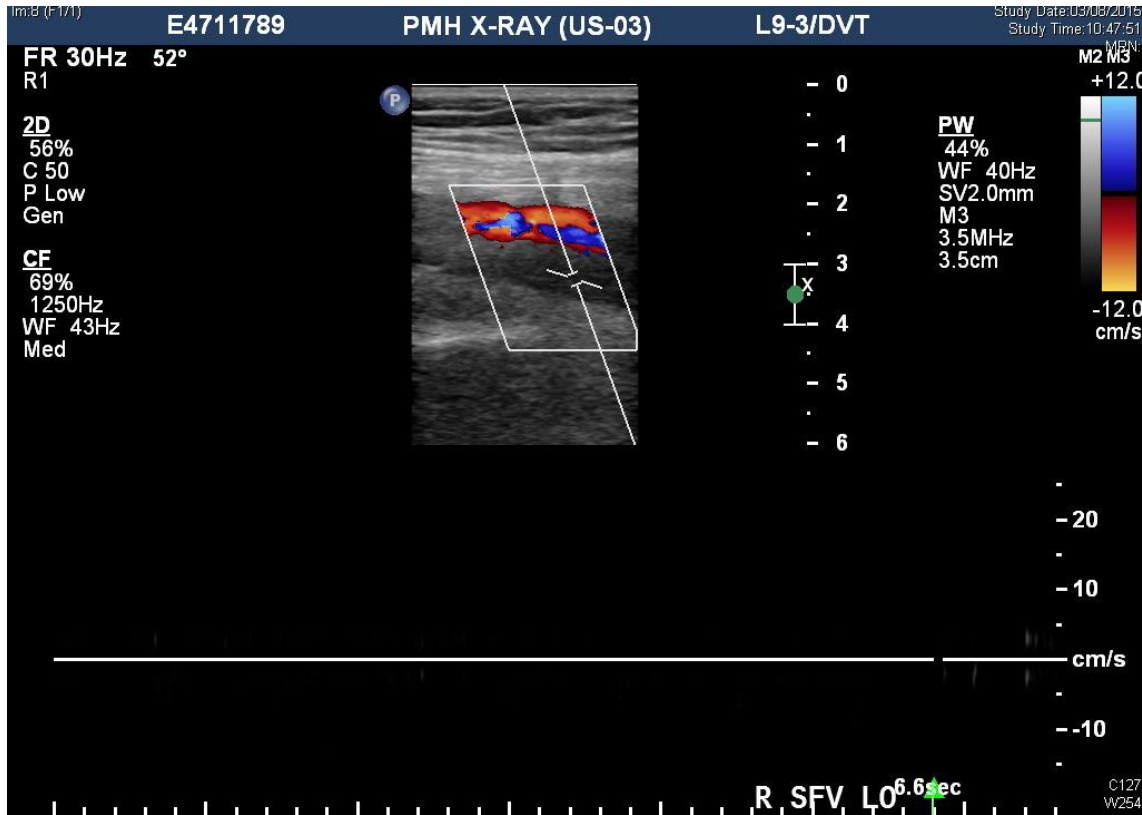
Compressibility of Right Common Femoral and Proximal Superficial Veins



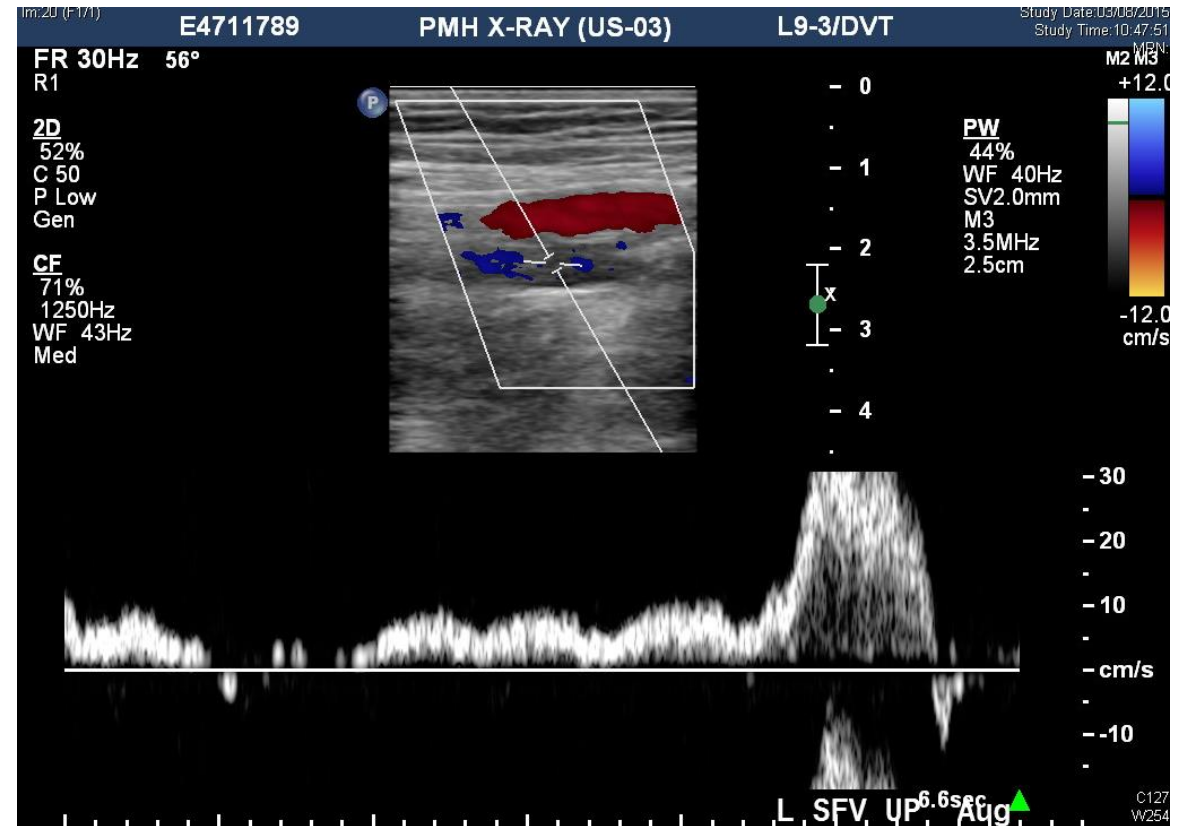
Rt Distal Superficial Femoral Vein



Lack of Augmentation



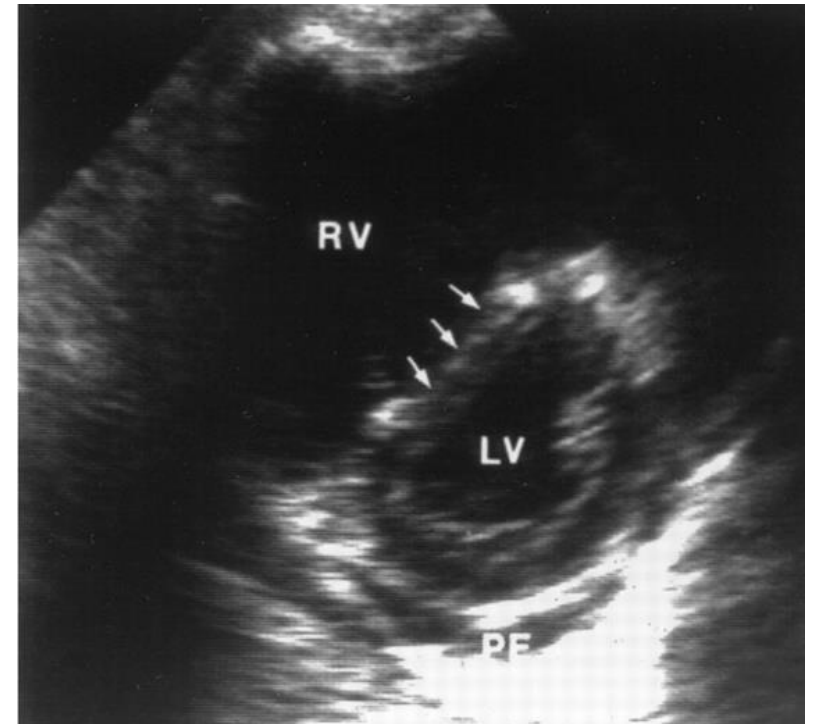
Abnormal Right side



Normal Left Side

Echocardiography

- Provides information of PE's effect on the right heart
- Rt heart hypokinesia and dilatation
- Septal bulging towards the left ventricle
- *McConnell's sign*
 - akinesia of the mid-free wall
 - normal motion of the apex
 - 77% sensitivity and a 94% specificity





European Heart Journal (2014) **35**, 3033–3080
doi:10.1093/eurheartj/ehu283

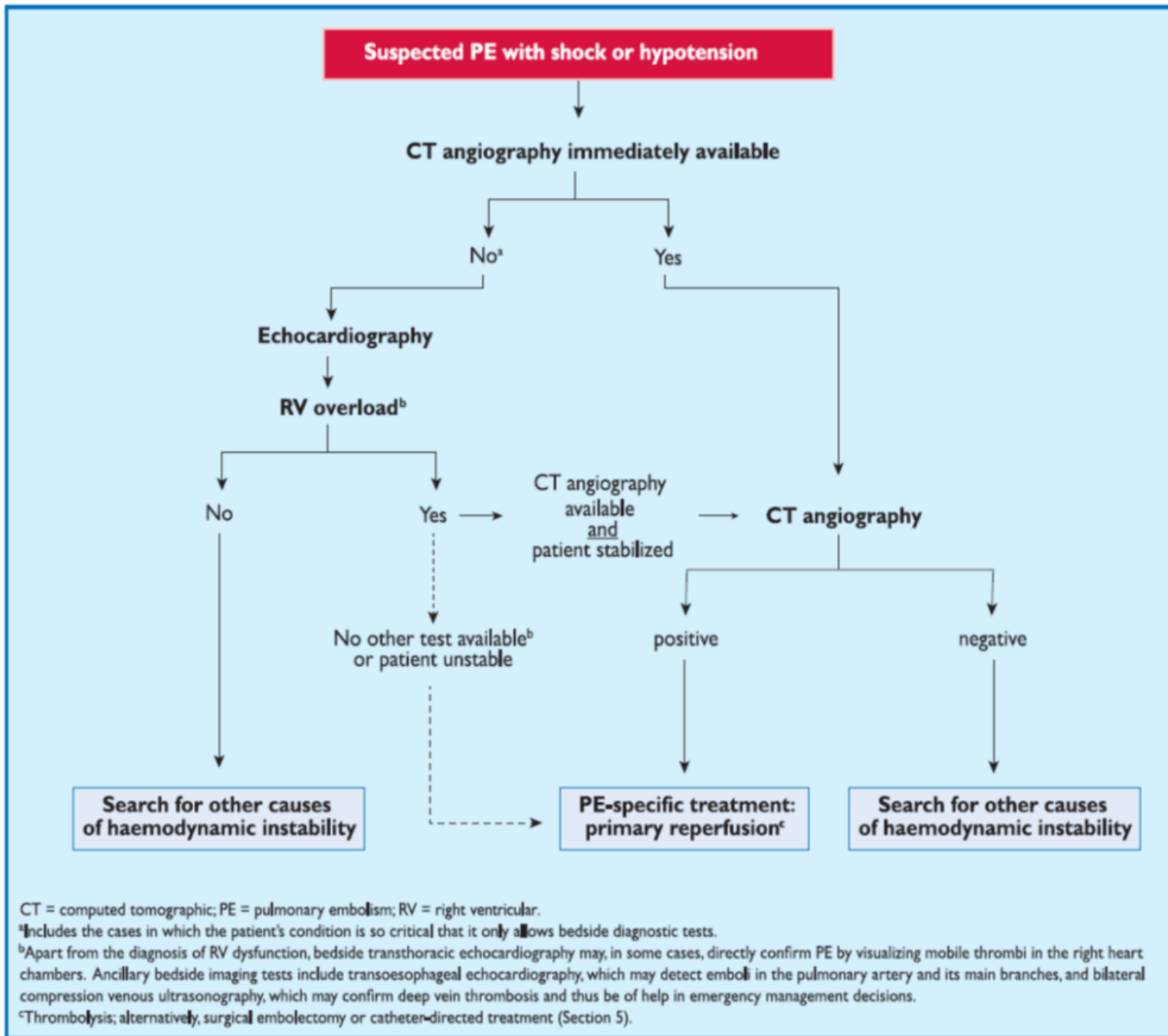
ESC GUIDELINES



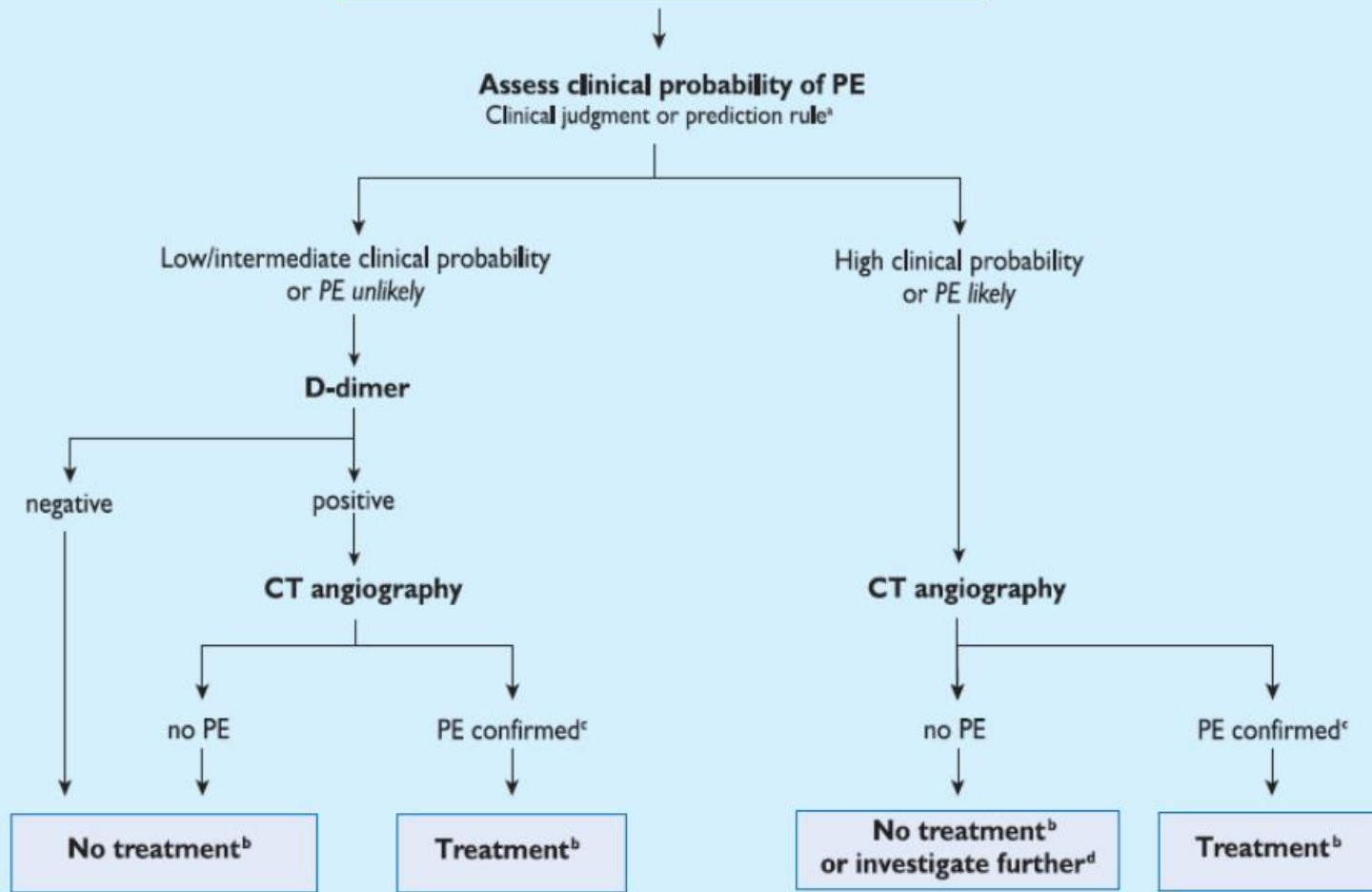
2014 ESC Guidelines on the diagnosis and management of acute pulmonary embolism

The Task Force for the Diagnosis and Management of Acute Pulmonary Embolism of the European Society of Cardiology (ESC)

Endorsed by the European Respiratory Society (ERS)



Suspected PE without shock or hypotension



CT = computed tomographic; PE = pulmonary embolism.

^aTwo alternative classification schemes may be used for clinical probability assessment, i.e. a three-level scheme (clinical probability defined as low, intermediate, or high) or a two-level scheme (PE unlikely or PE likely). When using a moderately sensitive assay, D-dimer measurement should be restricted to patients with low clinical probability or a PE-unlikely classification, while highly sensitive assays may also be used in patients with intermediate clinical probability of PE. Note that plasma D-dimer measurement is of limited use in suspected PE occurring in hospitalized patients.

^bTreatment refers to anticoagulation treatment for PE.

^cCT angiogram is considered to be diagnostic of PE if it shows PE at the segmental or more proximal level.

^dIn case of a negative CT angiogram in patients with high clinical probability, further investigation may be considered before withholding PE-specific treatment.

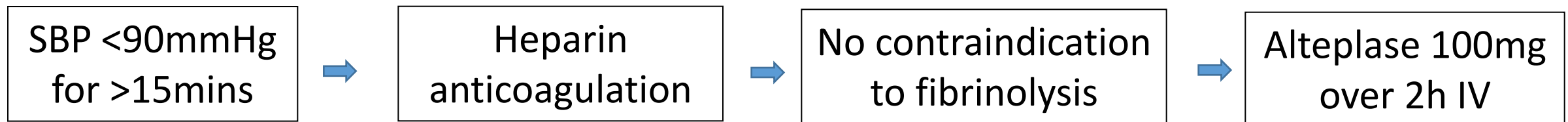
AHA Scientific Statement

Management of Massive and Submassive Pulmonary Embolism, Iliofemoral Deep Vein Thrombosis, and Chronic Thromboembolic Pulmonary Hypertension

A Scientific Statement From the American Heart Association

Michael R. Jaff, DO, Co-Chair; M. Sean McMurry, MD, PhD, Co-Chair; Stephen L. Archer, MD, FAHA; Mary Cushman, MD, MSc, FAHA; Neil Goldenberg, MD, PhD; Samuel Z. Goldhaber, MD; J. Stephen Jenkins, MD; Jeffrey A. Kline, MD; Andrew D. Michaels, MD, MAS, FAHA; Patricia Thistlethwaite, MD, PhD; Suresh Vedantham, MD; R. James White, MD, PhD; Brenda K. Zierler, PhD, RN, RVT; on behalf of the American Heart Association Council on Cardiopulmonary, Critical Care, Perioperative and Resuscitation, Council on Peripheral Vascular Disease, and Council on Arteriosclerosis, Thrombosis and Vascular Biology

AHA Guideline. Published in January 2011



Contraindications to thrombolytic therapy

• Absolute

- prior intracranial hemorrhage,
- Intracranial AV malformation
- ischemic stroke within 3 months,
- suspected aortic dissection,
- active bleeding or bleeding diathesis,
- recent surgery encroaching on the spinal canal or brain, and
- recent significant closed-head or facial trauma with radiographic evidence of bony fracture/brain injury

• Relative

- age >75 years;
- current use of anticoagulation;
- pregnancy;
- noncompressible vascular punctures;
- traumatic or prolonged CPR >10mins
- internal bleeding (within 2 to 4 weeks);
- uncontrolled HT on presentation
- major surgery within 3 weeks

Back to the question

BP 55/34, P 100, SpO2 100% despite increasing doses of inotropes and 2.5L of IVF

Cardiologist & ICU colleagues prefer to go for contrast CT thorax

Do you still agree with them?

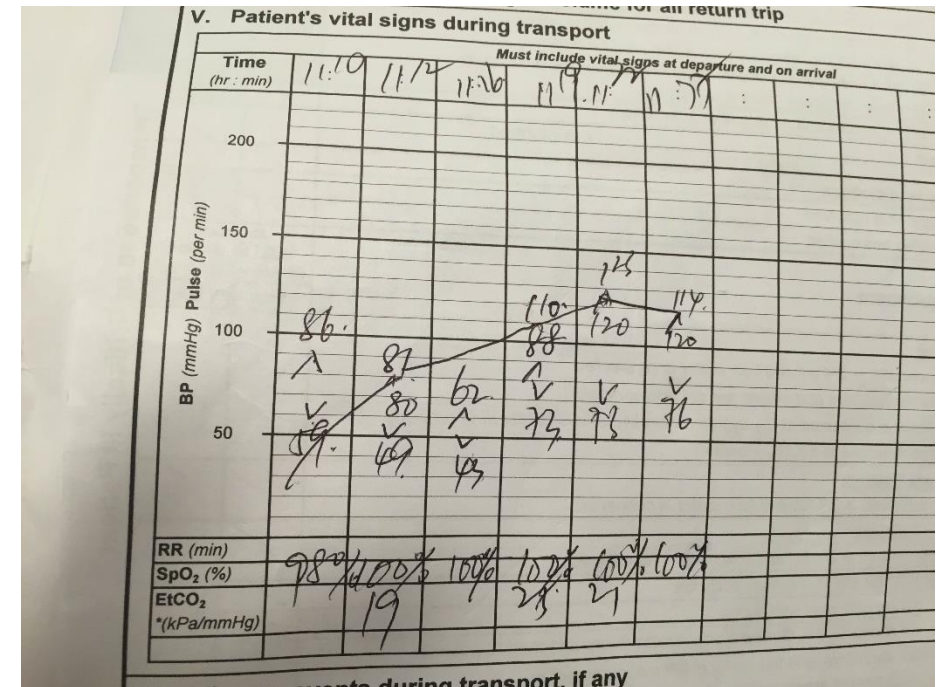
Emergency Physician's Decision:

Unfit for contrast CT
→ 6000iu TNK given

Part III: Outcome of patient

Progress

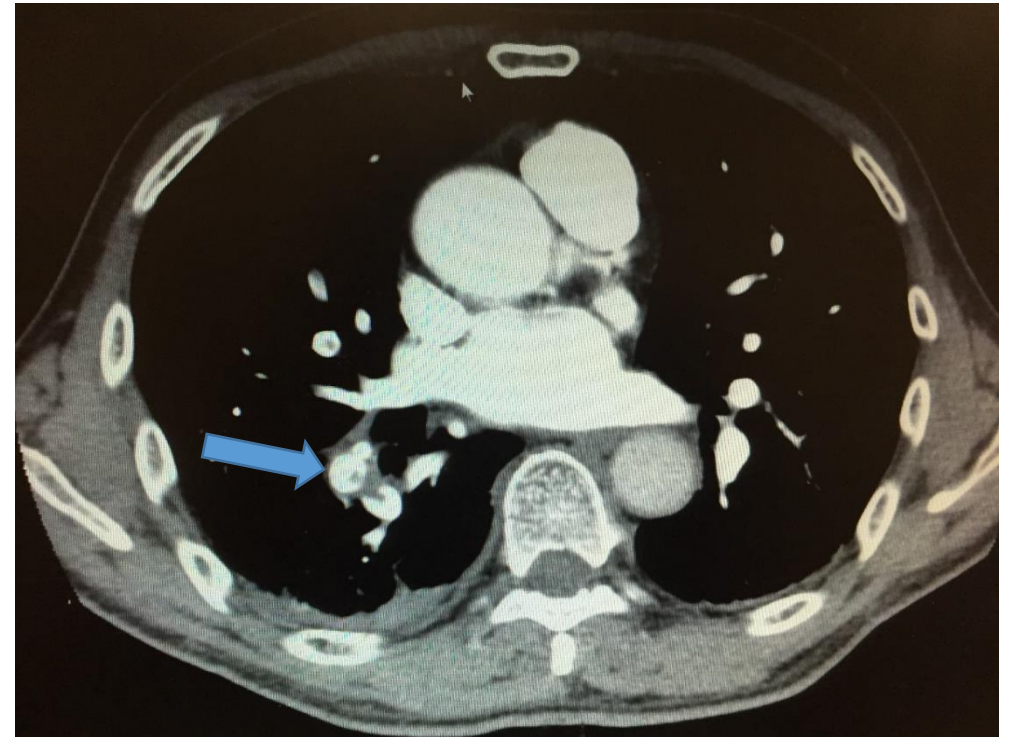
- BP improved to 86/55mmHg, P 92, on Adrenaline 22ml/Hr & Dopamine 30ml/Hr, pupils remain small
- Started to move and open eyes during transferal to ICU at 11:15

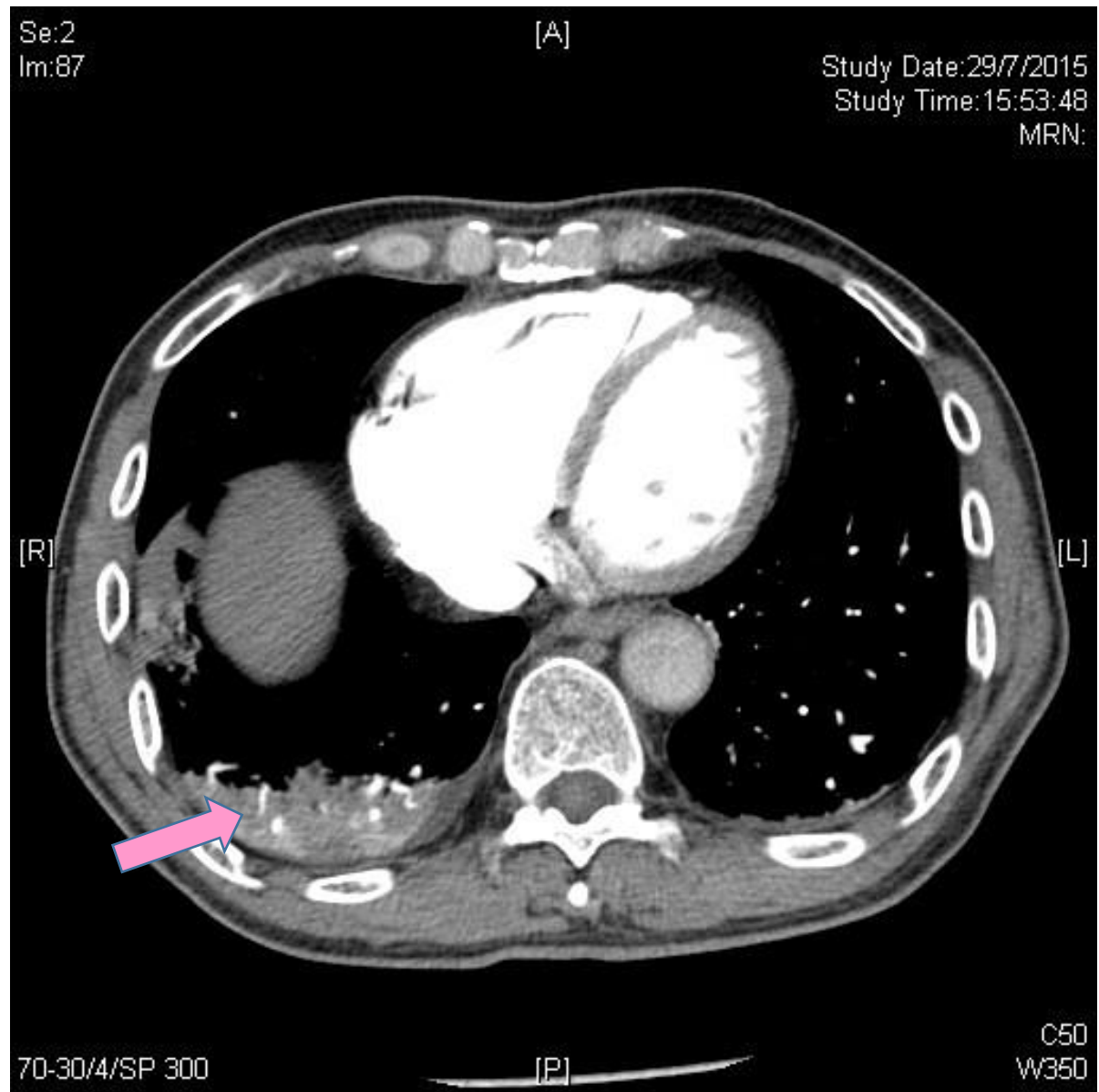
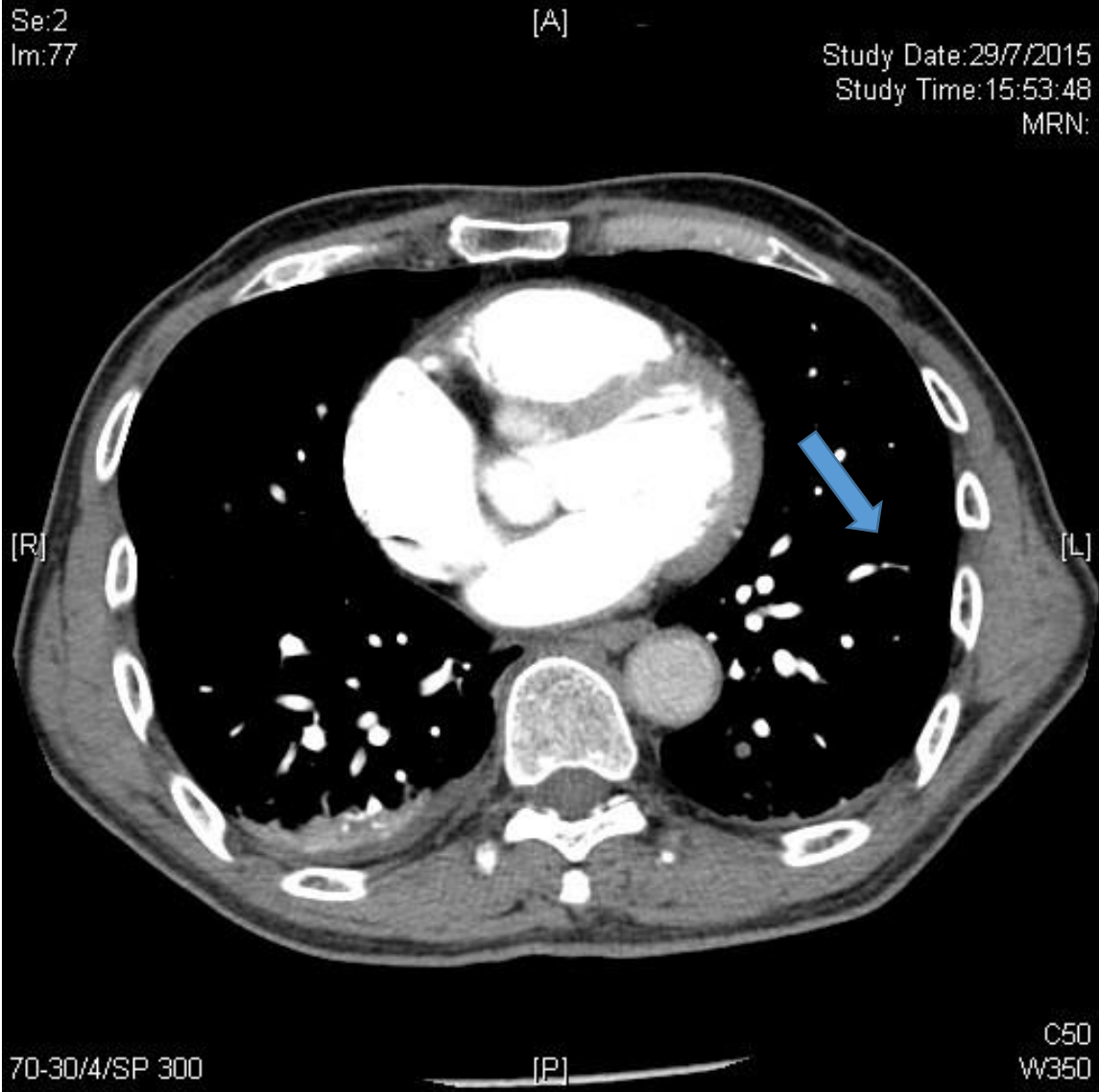


Progress at ICU

CT thorax done on the same day:

- Bilateral pulmonary embolism involving lobar and segmental branches
- Bilateral pleural effusion with atelectasis





Progress at ICU

- Repeated bedside echo: no more RV dilatation. LVEF 40%, no evidence of RV pressure overload
- WCC 12, Hb 12, plt 179, blood gas/LRFT normal
- Put on IV heparin
- Extubated at 12hrs after presentation
- Weaned off inotropes on day 2
- Transferred to general medical ward on day 3, started on warfarin

Further investigations

- Blood test for ANA, RF negative
- Tumour markers all within normal range
- Doppler USG of LL on day 4
 - DVT at distal right superficial femoral vein, collateral veins noted

Progress in General Medical Ward

- Seen by orthopedics
 - Wound well
 - Rt knee AROM 10-75 degrees limited by pain
 - Able to walk with stick
- No neurological impairment
- Discharged on day 11 with out-patient physio for knee mobilization

CT thorax 5 months later: resolution of PE
For lifelong anticoagulation

Summary

- Post-operative patient with immobilization
- Massive PE with shock and brief cardiac arrest
- Incorporate history, physical signs/symptoms with focused investigation, use of probability prediction rules to help make diagnosis
- Timely administration of thrombolytic agent
- Use of thrombolysis agent can be life-saving

References

- *Stavros V. Konstantinides, Adam Torbicki, Giancarlo Agnelli, Nicolas Danchin, David Fitzmaurice, Nazzareno Galiè, J. Simon R. Gibbs, Menno V. Huisman, Marc Humbert, Nils Kucher, Irene Lang, Mareike Lankeit, John Lekakis, Christoph Maack, Eckhard Mayer, Nicolas Meneveau, Arnaud Perrier, Piotr Pruszczyk, Lars H. Rasmussen, Thomas H. Schindler, Pavel Svitil, Anton Vonk Noordegraaf, Jose Luis Zamorano, Maurizio Zompatori* **2014 ESC Guidelines on the diagnosis and management of acute pulmonary embolism.** 29 August 2014
- Michael R. Jaff, M. Sean McMurtry, Stephen L. Archer, Mary Cushman, Neil Goldenberg, Samuel Z. Goldhaber, J. Stephen Jenkins, Jeffrey A. Kline, Andrew D. Michaels, Patricia Thistlethwaite, Suresh Vedantham, R. James White, Brenda K. Zierler and **Management of Massive and Submassive Pulmonary Embolism, Iliofemoral Deep Vein Thrombosis, and Chronic Thromboembolic Pulmonary Hypertension. A Scientific Statement From the American Heart Association**
- Carson, JL, Kelley, MA, Duff A, et al. "The clinical course of pulmonary embolism: One year follow-up of PIOPED patients." NEJM 1992; 326: 1240.
- The diagnostic approach to acute venous thromboembolism. Clinical Practice guideline. Am J Respir Crit Care Med, 1999; 160: 1043.
- [^](#) McConnell MV, Solomon SD, Rayan ME, Come PC, Goldhaber SZ, Lee RT (1996). "Regional right ventricular dysfunction detected by echocardiography in acute pulmonary embolism". Am. J. Cardiol. **78** (4): 469–73. [doi:10.1016/S0002-9149\(96\)00339-6](https://doi.org/10.1016/S0002-9149(96)00339-6). [PMID 8752195](https://pubmed.ncbi.nlm.nih.gov/8752195/).
- Stein, PD, Saltzman HA, Weg, JG. "Clinical Characteristics of patients with acute pulmonary embolism." Am J Cardiol 1991, 68: 1723

Thank you!